THE ANATOMICAL RECORD 299:484–491 (2016)

The Peridural Membrane of the Human Spine is Well Innervated

HEMMO A. BOSSCHER,* JAMES E. HEAVNER, PETAR GROZDANOV, IRFAN A. WARRAICH, MITCHELL S. WACHTEL, AND JANET DERTIEN
Texas Tech University Health Sciences Center, Lubbock, Texas

ABSTRACT

There is evidence that low back pain may originate from a peridural membrane (PDM) at the inferior and medial aspect of neural foramen of the lumbar spine. The objective of this investigation was to determine if this membrane contains neural elements suggestive of sensory innervation with nociceptive function. Spines of four embalmed and three non-embalmed human cadavers were dissected using a sagittal approach to the neural foramen. Seventeen samples of the peridural membrane overlying the neural foramen were collected for immunohistochemistry (IHC) examination by light microscopy and transmission electron microscopy (TEM). Chromagin tagged antibodies to protein gene product 9.5 (PGP9.5) and S-100, and fluorescent antibodies to substance P and calcitonin gene related peptide (CGRP) were used to label neural structures in tissue sections cut from paraffin embedded blocks. This approach allows good visualization of all neural elements, small sensory, and nociceptive nerve fibers in particular. Neural elements were found in all samples. Marked presence of small nerve fibers was observed in 12 of 15 samples. IHC and TEM evaluation revealed myelinated as well as unmyelinated fibers in the peridural membrane. CGRP and substance P immunoreactive fibers indicative of nociceptive function were abundant. These findings confirm and expand evidence that the peridural membrane in human is well innervated and contains sensory nociceptive nerve fibers suggestive of a nociceptive function of the membrane. Anat Rec, 299:484–491, 2016. © 2016 Wiley Periodicals, Inc.

Key words: back pain; spine; neural foramen; peridural membrane; innervation; nerve fibers; nociception; PGP9.5

INTRODUCTION

The peridural membrane (PDM) is a thin structure between the dura mater and vertebrae. It emerges from under the posterior longitudinal ligament, envelopes the dura, and extends into the intervertebral foramen (Bosscher, 2015). Histological examination of the peridural membrane has shown presence of nerve fibers and nerve endings (Luschka, 1850; Hovelaque, 1925; Bridge, 1959; Kumar et al., 1996). Low back pain may originate from this membrane at the inferior and medial aspect of neural foramen of the lumbar spine. (Heavner et al., 1991; Bosscher and Heavner, 2013).

The membrane has been described in detail by anatomist of the 19th and 20th century (Luschka, 1850; Hovelaque, 1925; Frykholm, 1951) and more recently by several other investigators (Ansari et al., 2012; Wiltse et al., 1993; Loughenbury et al., 2006; Breit et al., 2013).

This article was published online on 30 January 2016. After online publication, Table 1 headings were corrected. This notice is included in the online and print versions to indicate that both have been corrected on 13 February 2016.

*Correspondence to: Hemmo A. Bosscher, Grace Health System, Texas Tech University Health Sciences Center, Pain Management, 3505 88th Place, Lubbock, TX 79430. Tel: 806-785-5700. E-mail: Painmgmtdoc@hotmail.com

Received 13 July 2014; Revised 11 June 2015; Accepted 17 November 2015.

DOI 10.1002/ar.23315

Published online 11 January 2016 in Wiley Online Library (wileyonlinelibrary.com).

© 2016 WILEY PERIODICALS, INC.

In comparative biology, the peridural membrane is referred to as the endorachis (Wiedersheim, 1907; Kappers, 1926). The embryology of the peridural membrane is not known, but the membrane is best understood as a perichondrium derivative (Ansari et al., 2012; Newell, 1999). In the spine, formation of venous channels separates the peridural membrane from dura mater to form the epidural cavity and the epidural venous plexus with which the membrane is closely associated (Ansari et al., 2012; Newell, 1999). The membrane has been shown to protect the contents of the bony vertebral canal from intrusion of foreign material (Ansari et al., 2012).

The objective of the investigation presented here was to determine if the peridural membrane of the human spine contains sensory nerve fibers, supporting the thesis that the membrane might be a source of pain. Protein gene product 9 (PGP9) and S100 antibodies were used to locate neuronal tissue (Wilson et al., 1988; Kent and Clarke, 1991), in particular small nerve fibers. Antibodies to calcitonin gene related peptide (CGRP) and substance P were used to localize fibers that might be involved in nociception (Polak and Bloom, 1981). In addition to immunohistochemical (IHC) methods, transmission electron microscopy (TEM) was used to search for small myelinated nerve fibers or non-myelinated fibers (Murinson and Griffin, 2004; Faroni et al., 2014).

MATERIALS AND METHODS

Four embalmed and three unembalmed human cadavers were used for this investigation. The thoraco-lumbar spine between the vertebral body of T1 and the sacrum was removed en-block and divided in a sagittal plane at the midline. Multiple segments of the spine on both sides were evaluated and samples of the peridural membrane obtained for microscopic evaluation. The membrane was exposed and samples obtained by dissection using a dissecting microscope (Fig. 1). Starting from the midline, the dura and arachnoid were detached from the posterior longitudinal ligament and posterior wall of the spinal canal. The ligaments of Hoffmann and Trolard were cut. The nerve root sleeve and nerve roots were cut. In this manner, the dura, arachnoid, and the intradural nerve roots or spinal cord could be removed over the length of the spinal canal. Epidural fat tissue was removed to allow direct observation of the peridural membrane at the anterolateral, lateral, and posterior aspect of the spinal canal. Samples of the peridural membrane were then taken and placed in buffered formaldehyde. The peridural membrane overlying the cephalad aspect of the pedicle and covering the inferior internal orifice of the neural foramen was primarily selected. However, sections of the peridural membrane located more cephalad and dorso-lateral in the neural foramen were obtained from some of the specimen. The locations where the different samples of peridural membrane were collected are given in Table 1.

Peridural membrane samples were embedded in paraffin, sectioned (6 micron thick) and subsequently processed by a commercial laboratory (Quest Diagnostics) for IHC detection of protein gene product 9.5 (PGP9.5).

Two pathologists evaluated the peridural membrane samples independently and results were reviewed with the authors. Samples were considered positive if small nerve fibers stained for PGP9.5 were present. Innervation was rated using the following scale—mild or slightly positive if only few PGP9.5 positive structures per high power field (HPF) (200×) were present, moderate if multiple positive small nerve fibers were observed throughout the sample and marked if there was an abundance (too numerous to count) of positive small nerve fibers noted. Presence of nerve bundles and inflammatory cells was recorded. Immunofluorescence techniques, using polyclonal (CGRP: AlexaFluor 488 donkey anti rabbit IgG) and monoclonal antibodies (substance P AlexaFluor 488 donkey anti goat IgG) were used to investigate presence of CGRP and Substance P (SP) in nerve fibers in the samples of the peridural membrane at L1-2, L2-3, and L3-4 (Table 1: Samples 1, 14, 16; FDNeurotech). Images were taken on an A1 confocal Nikon microscope. Images were sequentially collected in all three channels pre-set on the microspore corresponding to 4',6-diamidino-2-phenylindole (DAPI), fluorescein (FITC), and tetramethylrhodamine (TRICT). Z-stack sections were collected with a step of 0.2 μm and maximum intensity images were created from these z-stacks using the Nikon Instruments (NIS)-elements software. Samples were evaluated by two of the authors and considered positive if presence of labeled antibodies to substance P and CGRP in nerve fibers could be demonstrated.

Microscopic evaluation of the peridural membrane, using Haematoxyline and Eosin (H-E) stain and antibodies to S-100, were performed in samples 16 and 17.

Two sections of the peridural membrane were obtained from the dorso-lateral aspect of the spinal canal at the inferior aspect of the neural foramen of L2-L3 and L3-4, placed in buffered glutaraldehyde, and evaluated by transmission electron microscopy. Images were evaluated for presence of nerve fibers and for the type of nerve fibers (size, myelinated or unmyelinated, organization) found in the peridural membrane.

RESULTS

PGP9.5

Seventeen samples were evaluated for the presence of PGP9.5 (Table 1). PGP9.5 positive nerve fibers were present in all samples (Fig. 2). Sixteen of 17 samples showed multiple myelinated and unmyelinated fibers per HPF (×200). Fourteen samples showed an abundance of fibers. Most samples were obtained from the suprapedicular area of the vertebral bodies of the thoraco-lumbar spine. Some samples of the peridural membrane were obtained from the cephalad and dorso-lateral aspect of the neural foramen. No difference was noted with respect to the distribution of nerve fibers and nerve bundles in the different areas sampled. Nerve bundles in the peridural membrane were seen in all but three samples (Fig. 3). Nerve fibers observed in the substance of the peridural membrane generally were not associated with a blood vessel (Fig. 2). No obvious differences were noted between peridural membrane obtained from embalmed and non-embalmed cadavers.

CGRP and Substance P

Immune reactivity with antibodies to CGRP and substance P was shown in nerve fibers in sections of the PDM taken from embalmed and non-embalmed cadavers (Figs. 4 and 5).

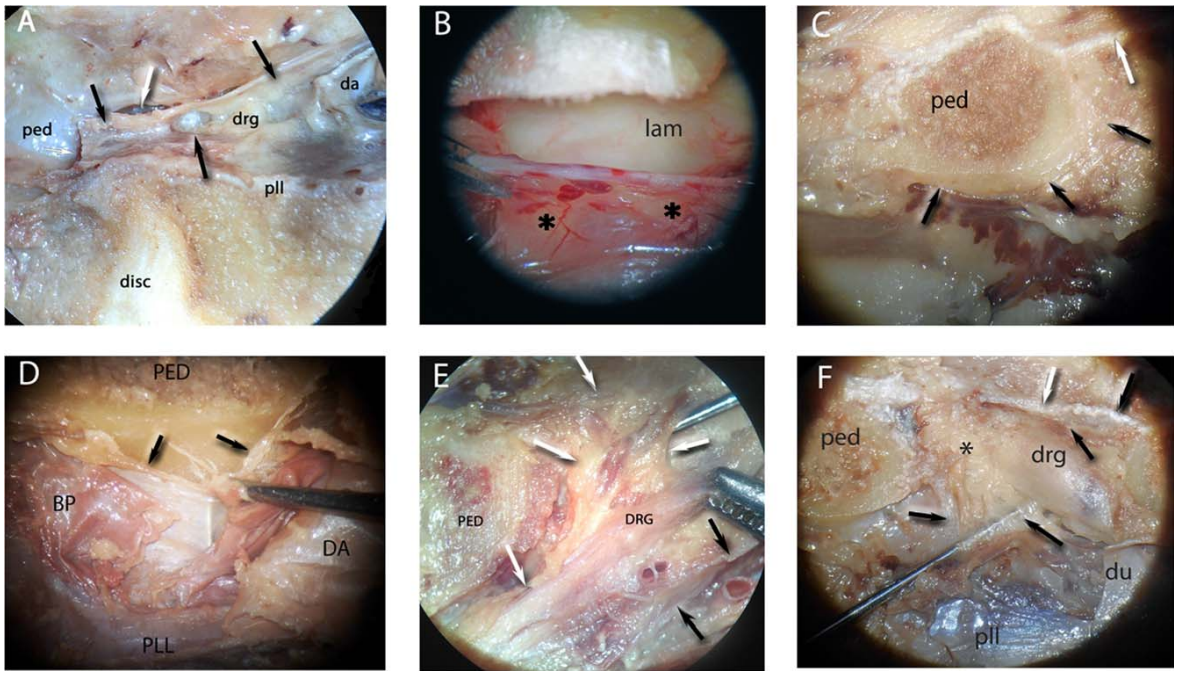

Fig. 1. Gross anatomical dissection. (A) Peridural membrane in the neural foramen. Embalmed cadaver. Sagittal view of the medial wall and neural foramen of the lumbar spine. Right is cephalad, left is caudal, top is posterior, and bottom is anterior. Da – dura, disc – intervertebral disc, drg – dorsal root ganglion, ped – pedicle, pll – posterior longitudinal ligament. The peridural membrane forms a funnel shaped cuff around the dorsal root (black arrows). A suprapedicular compartment is formed lateral to the peridural membrane in the inferior neural foramen (white arrows). (B) Peridural membrane covering the lamina and pedicle. Unembalmed cadaver. View of the dorsal and lateral wall of the lumbar spinal canal at L2–L4. Right is cephalad. Left is caudal. Top is dorsal. Bottom is ventral. Lam – lamina. Peridural membrane (star). (C) Peridural membrane covering the medial wall of the pedicle. Embalmed cadaver. Coronal view of the dorsal wall of the lumbar spinal canal at L2–L4. Left is caudal. Right is cephalad. Top is lateral and bottom is medial. Da – dura mater, lf – ligamentum flavum, ped – pedicle. Center – peridural membrane (black arrows). Fibrous connection between dura and peridural membrane (white arrow). (D) Peridural membrane in the anterior epidural space and covering the pedicle. Embalmed cadaver. Coronal/sagittal view of the lumbar spinal canal at L2–L4. Left is caudal. Right is cephalad. Top is lateral and bottom is medial. Bp – Batson's plexus, da – dura, ped – pedicle, pll – posterior longitudinal ligament. Peridural membrane in the center (black arrows). (E) Peridural membrane in the posterior spinal canal extending laterally into the posterior neural foramen. Embalmed cadaver. View of the posterior wall of the spinal canal and neural foramen at L2-4. Right is cephalad, left is caudal, top is medial, and bottom is lateral. Drg – dorsal root ganglion, ped – pedicle. The peridural membrane covers but is not attached to the posterior wall of the neural foramen and continues posterior and cephalad to the dorsal root ganglion (white arrows). Operculum of Forestier (black arrows). (F) Peridural membrane in the anterior spinal canal extending laterally into the anterior neural foramen. Embalmed cadaver. View of the anterior wall of the spinal canal and neural foramen at L2-4. Right is cephalad. Left is caudal. Top is lateral. Bottom is medial. Drg – dorsal root ganglion, ped – pedicle, pll – posterior lateral ligament. The peridural membrane covers, but is not attached to, the anterior wall of the neural foramen and continues anterior, cephalad, and lateral to the dorsal root ganglion (black arrows). Operculum of Forestier adjacent to the DRG (white arrow). Adipose tissue filling the space between the DRG and the PDM (star).

General Morphology of PDM Samples

Histological evaluation of the PDM showed loose and dense connective tissue, fat tissue, arterial and venous blood vessels, and lymphatics (Figs. (2 and 3), and 6). Inflammatory cells such as histiocytes and lymphocytes were present in most samples (Fig. 6A,B). Nerve bundles in the peridural membrane were demonstrated in all but three samples and were identified using morphological characteristics (Fig. 3A), immune reactivity to S-100 (Fig. 3B), and PGP9.5 (Fig. 2). By subjective measure, there was an inverse relationship between density of nerve fibers and density of inflammatory cells.

Transmission Electron Microscopy

Ultra-high resolution electron microscopy (EM) of the peridural membrane showed presence of myelinated nerve fibers unmyelinated nerve fibers with variable diameter (Fig. 7). Presence of unmyelinated axons appearing as a Remak bundle was demonstrated in several nerves obtained from PDM tissue (Fig. 7B and C).

DISCUSSION

The most important finding of this investigation is the presence of small PGP 9.5 positive nerve fibers with nociceptive function based on CGRP and substance P IHC results (Meyer et al., 2006; Polak and Bloom, 1981). This suggests a nociceptive function of the peridural membrane of the human spine.

Few studies are available on the innervation of the peridural membrane. Luschka, Hovalaque, and Bridge described autonomic and somatic nerve fibers in the membrane (Luschka, 1850; Hovelaque, 1925; Bridge,

TABLE 1. Presence of PGP9.5 positive nerve fibers and bundles plus inflammation in peridural membrane obtained from the spinal neural foramen in human.

Sample	Embalmed	Level	Location (Neural foramen)	Small fibers	Nerve bundles	Inflammation
1	+	L2-3	Cephalad posterior	Marked	+	+
2	+	L4-5	Lateral	Marked	–	–
3	+	L3-4	Cephalad posterior	Marked	+	+
4	+	L3-4	Caudal	Marked	+	+
5	+	L4-5	Caudal	Marked	+	+
6	+	L2-3	Caudal	Marked	+	+
7	–	L3-4	Caudal	Marked	+	–
8	–	L2-3	Caudal	Marked	+	+
9	–	T3-4	Caudal	Marked	–	–
10	–	T5-6	Caudal	Mild	+	+
11	–	L1-2	Caudal lateral	Marked	+	–
12	–	L2-3	Posterior lateral	Marked	–	–
13	–	L3-4	Caudal	Moderate	+	+
14	–	L4-5	Inferior lateral	Moderate	+	+
15	–	L4-5	Posterior lateral	Marked	+	+
16	–	L1-2	Posterior lateral	Marked	+	+
17	–	L4-5	Lateral	Marked	+	+

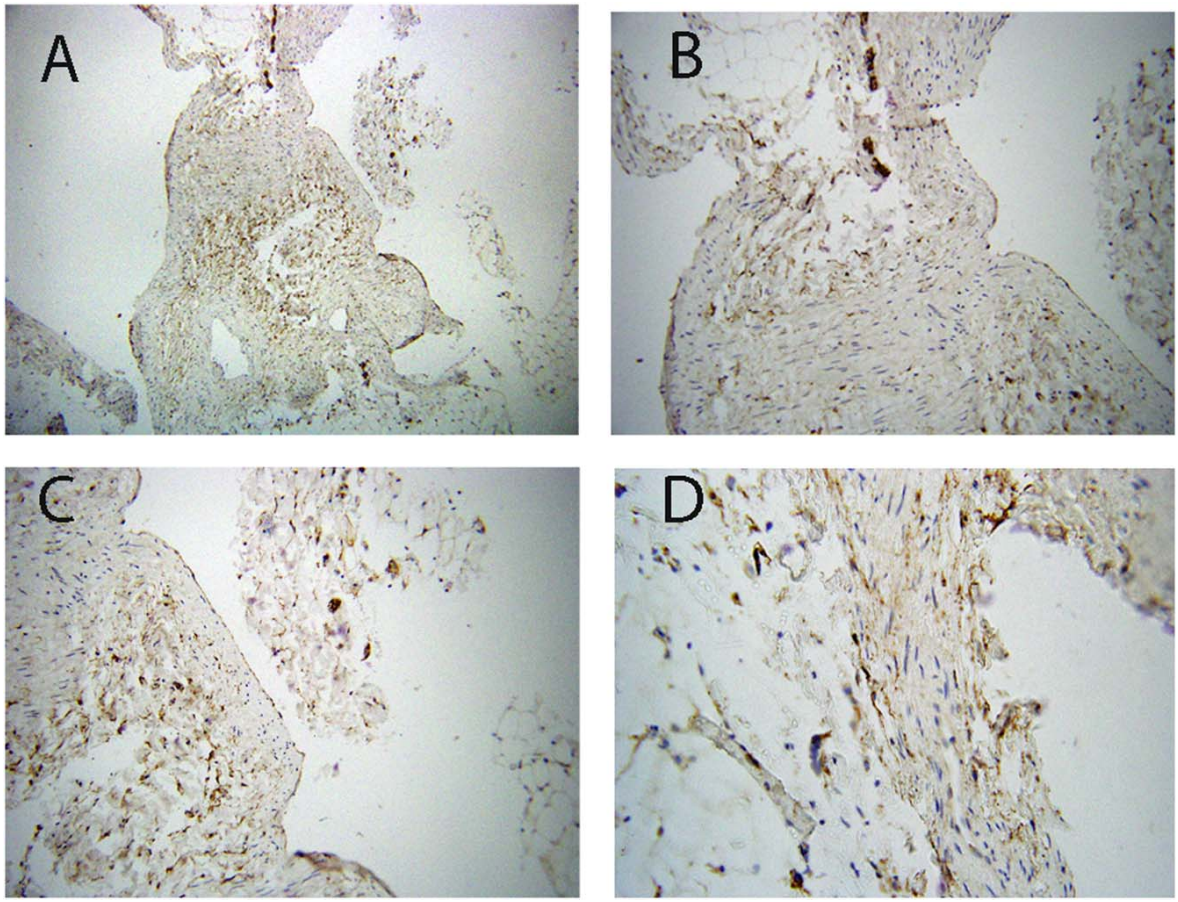

Fig. 2. Light microscopy showing PGP9.5 (brown) immune reactivity. (A) Perpendicular cut section of the peridural membrane obtained from the dorsolateral wall of the spinal canal at the inferior and inner aspect of the neural foramen of the spinal canal at the level of L3 and 4. (Magnification 50×). Gross distribution of PGP positive tissue in the membrane. (B) Higher magnification of sample A. (100×). Shows PGP positive nerve fibers, fibrous and adipose tissue. (C) Section of sample as 2A. (100×). As in Fig. 2B, notice abundance of PGP positive nerve fibers. (D) Section of sample as 2A. (200×). Shows individual PPGP9.5 positive nerve fibers within the membrane.

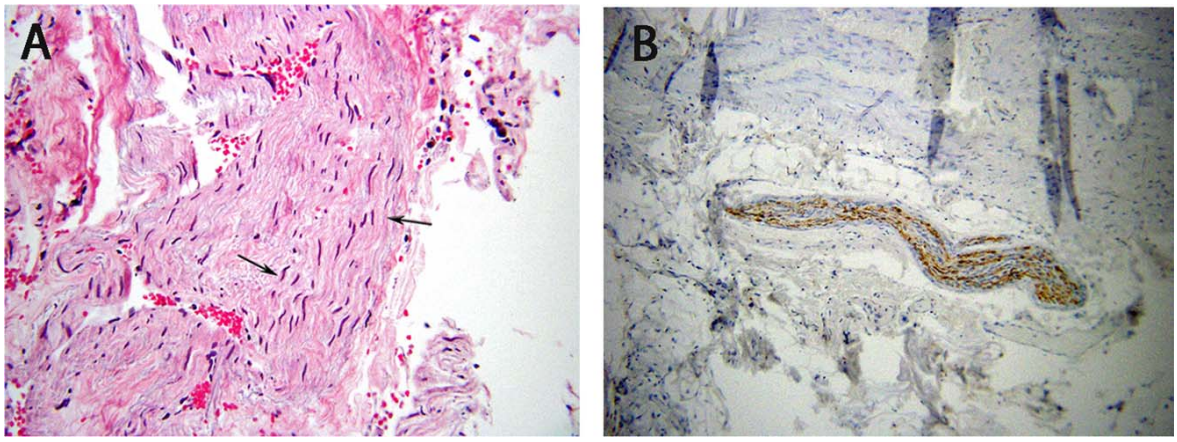

Fig. 3. Light microscopy. (A) Haematoxyline and eosin stain of peridural membrane, at L3 and 4. Arrows indicate a large nerve bundle. (Magnification 400×). (B) S-100 immune reactivity (brown) of peridural membrane at level of L3 and 4. (100×).

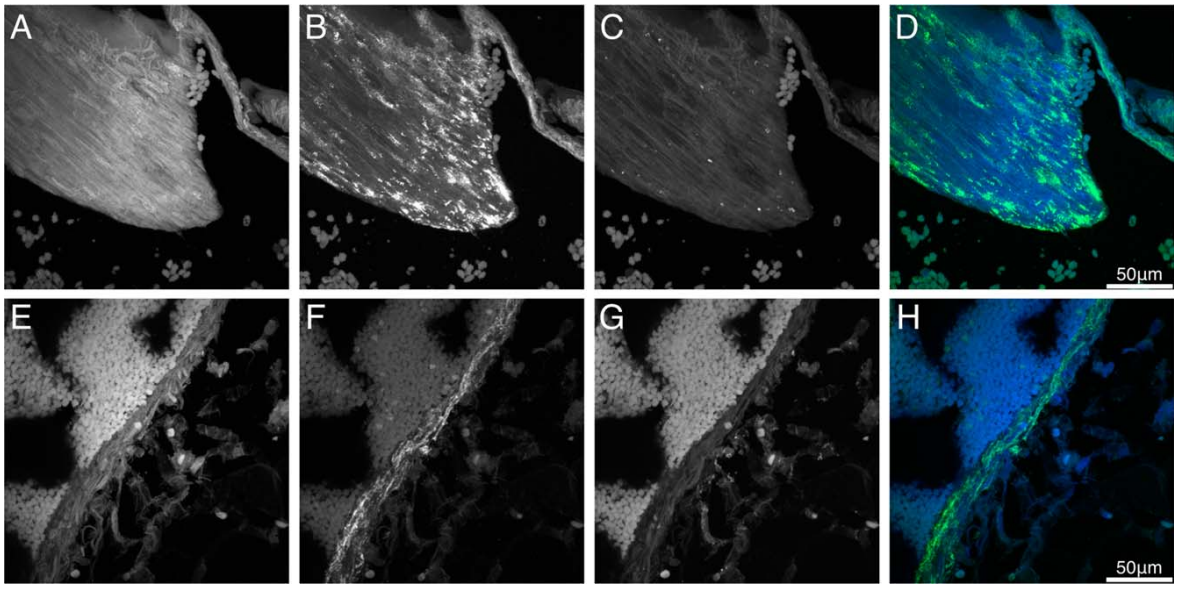

Fig. 4. Confocal microscopic images showing substance P staining of the peridural membrane. White bar – 50 µm. (A and E) 4′,6-diamidino-2-phenylindole (DAPI) staining of the nuclei; shows the morphology of the sample. (B and F) Green channel corresponding to fluorescein (FITC). Substance P positive fibers are bright. (C and G) Tissue auto-florescence collected in the red channel corresponding to tetramethylrhodamine (TRICT). (D and H) Merged DAPI and substance P staining; substance P positive fibers show green.

1959). Kumar et al. demonstrated immune reactivity to CGRP and SP of nerve fibers in the peridural membrane of the rat (Kumar et al., 1996). However, there is indirect support for presence of nociceptive nerve fibers in the peridural membrane from earlier studies into the innervation of the spine. Nerve fibers, sensory and nociceptive, have been demonstrated in the outer layers of the intervertebral disc, ligamentum flavum, dura, and posterior longitudinal ligament (Bridge, 1959; Bucknill et al., 2002; Groen et al., 1990; Kimmel, 1961; Malinsky, 1959; Roofe, 1940; Stillwell, 1956). Since a peridural membrane is not mentioned explicitly in any of these investigations, it is conceivable that some nerve fibers identified in these layers were actually part of the peridural membranous cover of these structures.

Nerve bundles can be demonstrated throughout the peridural membrane using morphological characteristics of nerve tissue with H-E stain or using labeled antibodies to S-100 protein. Axons in apparent Remak configuration, demonstrated with electron microscopy, suggests that

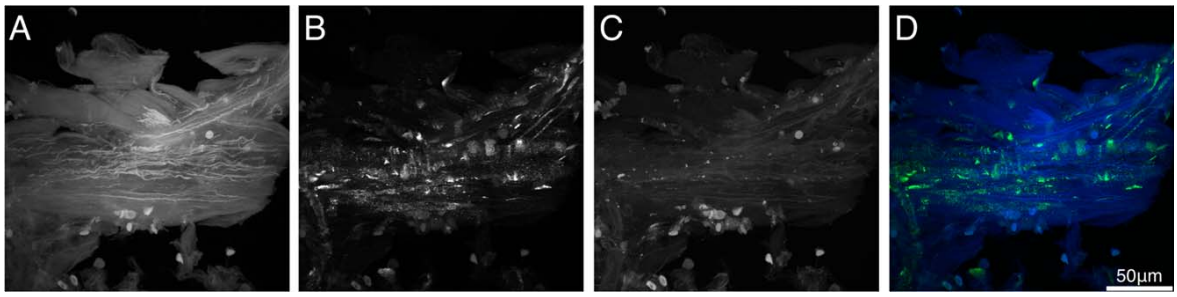

Fig. 5. Confocal microscopic images showing CGRP staining of the peridural membrane. (A) Auto-fluorescence in the DAPI channel; shows the morphology of the sample. (B) Green channel corresponding to fluorescein (FITC); CGRP positive fibers are bright. (C) Tissue auto-florescence collected in the red channel corresponding to tetramethylrhodamine (TRICT). (D) Merged DAPI channel and CGRP staining. CGRP positive fibers show green. White bar – 50 μm.

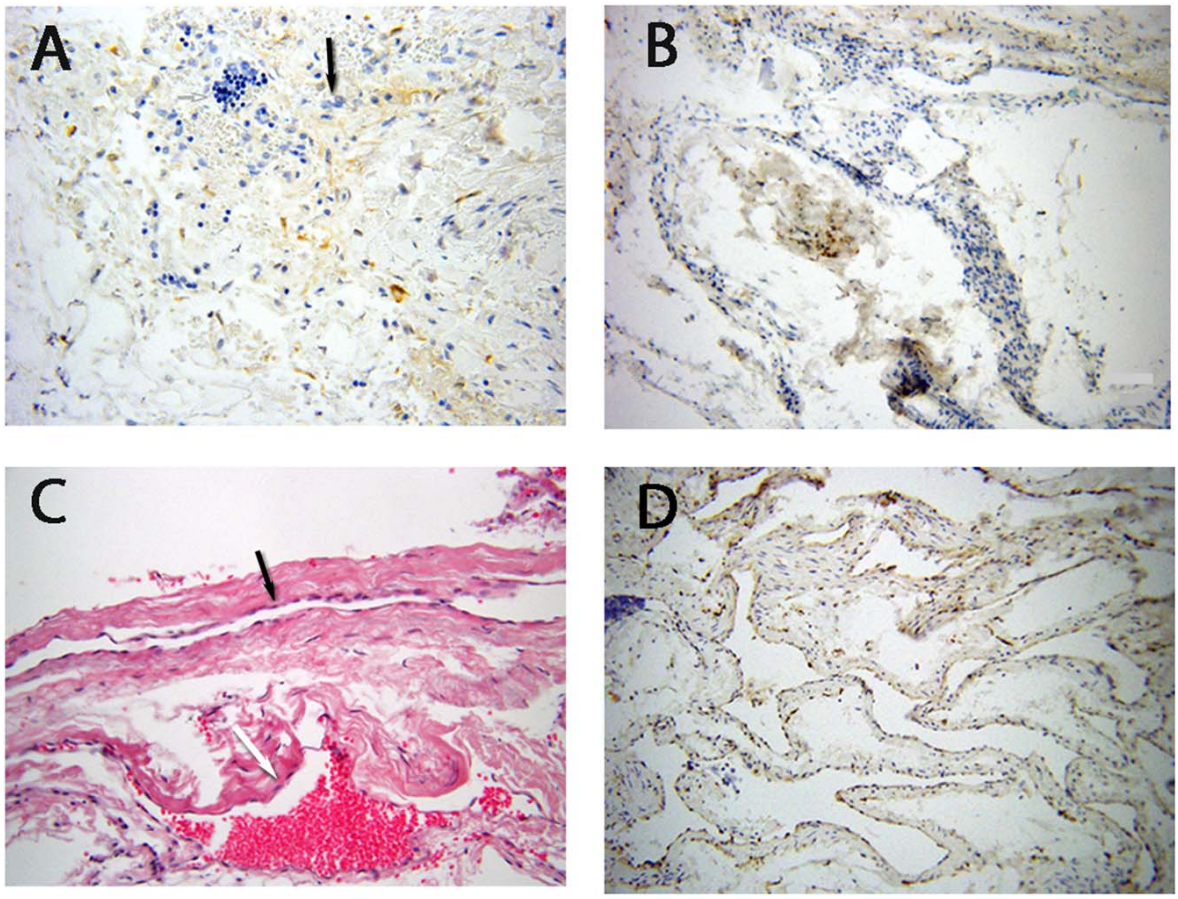

Fig. 6. Light microscopy. (A) PGP9.5 (brown) reactivity in a section of the peridural membrane. Chronic inflammation of the peridural membrane. A cluster of lymphocytes and histiocytes can be seen (white arrow). Isolated histiocytes are seen (e.g. black arrow). Sample obtained from the inferior and inner aspect of the neural foramen L3 and 4. (Magnification 100×). (B) Extensive distribution of lymphocytes and histiocytes is present throughout this section of the membrane. No immune reactivity to PGP9.5 (brown) is present in areas of inflammation ("Crowding out"). Sample obtained from the dorsolateral wall of the spinal canal at the inferior and inner aspect of the neural foramen at L3 and 4. (50×). (C) A vessel identified as a vein or venous sinus (white arrow) and a vessel with characteristics of a lymphatic (black arrow). Haematoxyline and Eosin stain. (100×). (D) A cluster of vessels with characteristics of lymph vessels. Notice the close association with PGPG9.5 positive fibers (brown). Sample of the peridural membrane obtained from the dorsolateral wall of the spinal canal at the inferior and inner aspect of the neural foramen L3 and 4. (50×).

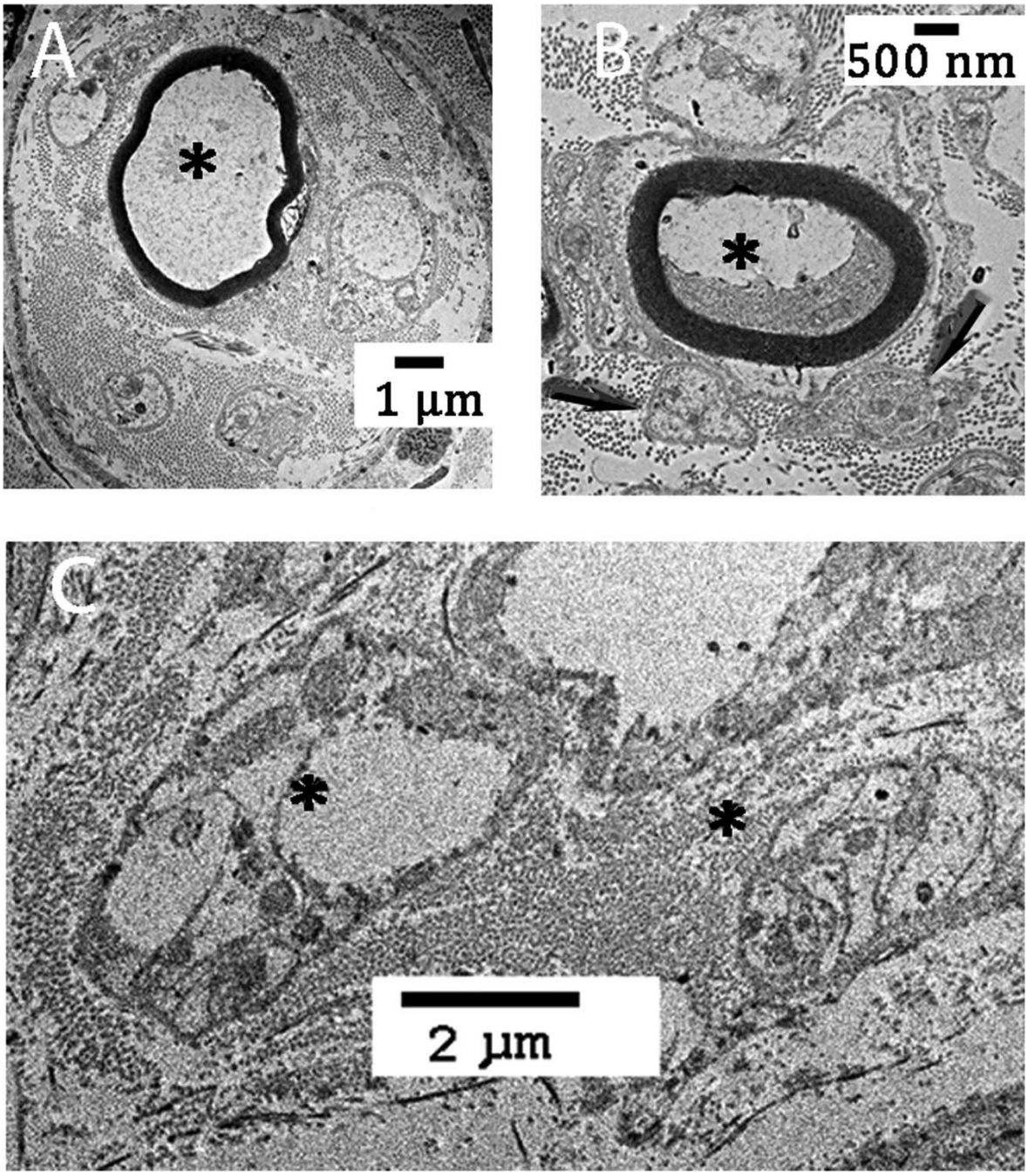

Fig. 7. Transmission electron microscopy. (A) Nerve bundle containing a myelinated axon and multiple unmyelinated axon grouped in Remak bundles in peridural membrane obtained from the inferior and inner aspect of the neural foramen of L3-4. (B) Myelinated axon (star) and unmyelinated axons in Remak bundles (white arrows) in peridural membrane obtained from the inferior and inner aspect of the neural foramen of L3-4. (C) Nerve bundle in peridural membrane obtained from the inner and inferior aspect of the neural foramen of L2-3. Several axon configurations, which appear as Remak bundles, can be identified (stars).

these nerve bundles contain C-fibers (Murinson and Griffin, 2004; Faroni et al., 2014). Density of small PGP9.5 positive nerve fibers in the PDM was variable in samples taken from different cadavers, among different vertebral levels, and over the length of the peridural membrane at one vertebral level. Presence of nerve fibers and positive

staining may depend on the physiological activity of the membrane. Indeed, some samples showed an abundance of histiocytes, lymphocytes, and possibly mast cells, indicative of a chronic inflammatory process (Fig. 6A,B). The number of nerve fibers may vary depending on the stage and intensity of chronic inflammation. The presence of a noxic stimulus (i.e. through the release of inflammatory mediators from a degenerated intervertebral disc) stimulates the growth of capillaries and nerve fibers into the area of inflammation (Ghilardi et al., 2012). An inflammatory process may also decrease density of nerve fibers as a result of crowding by inflammatory cells or by chemical alteration of epitope structure and diminishing antibody detection (Hukkanen et al., 1992) (Fig. 6B).

Limitations

This investigation is limited to anatomical examination that leads to deduction of function. This is offset by clinical observation regarding function (see below) as well as substantial literature linking our anatomical observations to function.

Summary

The peridural membrane in the inferior aspect of the lumbar and thoracic spine in human cadavers was examined by light microscopy, immunohistochemistry, and electron microscopy. All but one of the samples contained a moderate or marked number of PGP9.5 positive fibers indicating that the peridural membrane is a well-innervated structure. Presence of CGRP and SP positive nerve fibers and demonstration of small unmyelinated nerve fibers using electron microscopy, suggests that these fibers have nociceptive function. This is consistent with epiduroscopy findings (Bosscher and Heavner, 2013) as well as pain relief obtained by percutaneous ablation and curettage of the intervertebral foramen (PACIF) in humans with chronic low back pain (Bosscher and Heavner, 2015).

ACKNOWLEDGEMENT

The authors thank Mary Catherine Hastert and Jan van Weering for assistance with electron microscopy.

LITERATURE CITED

Ansari S, Heavner JE, McConnell DJ, Azari H, Bosscher HA. 2012. The peridural membrane of the spinal canal: a critical review. Pain Pract 12:315–325.

Bosscher HA, Heavner JE. 2013. Lumbosacral epiduroscopy findings predict treatment outcome. Pain Pract 14:506–514.

Bosscher HA, Heavner JE. 2015. Treatment of common low back pain. A new approach to an old problem. Pain Pract 15:509–517.

Breit S, Giebels F, Kneissl S. 2013. Foraminal and paraspinal extraforaminal attachments of the sixth and seventh lumbar spinal nerves in large breed dogs. Vet J. 197:631–638.

Bridge CJ. 1959. Innervation of spinal meninges and epidural structures. Anat Rec 133:553–563.

Bucknill AT, Coward K, Plumpton C, Tate S, Bountra C, Birch R, Sandison A, Hughes SP, Anand P. 2002. Nerve fibers in lumbar spine structures and injured spinal roots express the sensory neuron-specific sodium channels SNS/PN3 and NaN/SNS2. Spine 27:135–140.

Faroni A, Castelnovo LF, Procacci P, Caffino L, Fumagalli F, Melfi S, Gambarotta G, Bettler B, Wrabetz L, Magnaghi V. 2014. Deletion of GABA-B receptor in Schwann cells regulates remak bundles and small nociceptive C-fibers. Glia 62:548–565.

Frykholm R. 1951. Cervical epidural structures, periradicular, and epineurial sheaths. Acta Chir Scand 102:10–20.

Ghilardi JR, Freeman KT, Jimenez-Andrade JM, Coughlin KA, Kaczmarska MJ, Castaneda-Corral G, Bloom AP, Kuskowski MA, Antyh PW. 2012. Neuroplasticity of sensory and sympathetic nerve fibers in a mouse model of a painful arthritic joint. Arthritis Rheum 64:2223–2232.

Groen GJ, Baljet B, Drukker J. 1990. Nerves and nerve plexuses of the lumbar vertebral column. Amer J Anat 188:282–296.

Heavner JE, Cholkhavatia S, Kizelshteyn G. 1991. Percutaneous evaluation of the epidural and subarachnoid space with the flexible fiberscope. Reg Anesth 15S:85.

Hovelaque A. 1925. Le nerf sinu-vertebral. Ann Anat Path Med Chir 2:435–443.

Hukkanen M, Konttinen YT, Rees RG, Santavirta S, Terenghi G, Polak JM. 1992. Distribution of nerve endings and sensory neuropeptides in rat synovium, meniscus, and bone. Int J Tissue React 14:1–10.

Kappers A. 1926. The meninges in lower vertebrates as compared to those in mammals. Arch Neurol Psych 15:281–296.

Kent C, Clarke PJ. 1991. The immunolocalization of the neuroendocrine specific protein PGP9.5 during neurogenesis in the rat. Brain Res Dev Brain Res 58:147–150.

Kimmel DL. 1961. Innervation of spinal dura mater and dura mater of the posterior cranial fossa. Neurology 11:800–809.

Kumar R, Berger RJ, Dunsker SB, Keller JT. 1996. Innervation of the spinal dura. Myth or reality? Spine (Phila Pa 1976) 21:18–26.

Loughenbury PR, Wadhwani S, Soames RW. 2006. The posterior longitudinal ligament and peridural (epidural) membrane. Clin Anat 19:487–492.

Luschka H. 1850. Die nerven des menschlichen werbelkanals. Tubingen: Laupp.

Malinsky J. 1959. The ontogenetic development of nerve terminations in the intervertebral discs of man. Acta Anat 38:96–113.

Meyer RA, Ringkamp M, Campbell JN, Srinivasa NR. 2006. Peripheral mechanisms of cutaneous nociception. In: McMahon SB, Koltzenburg M, editors. Wall and Melzack's textbook of pain. 5th ed. Philadelphia: Elsevier. p 3–34.

Murinson BB, Griffin JW. 2004. C-fiber structure varies with location in peripheral nerve. J Neuropathol Exp Neuro 63:246–254.

Newell RL. 1999. The spinal epidural space. Clin Anat 12:375–379.

Polak JM, Bloom SR. 1981. The peripheral substance P-ergic system. Peptides 133:133–148.

Roofe PG. 1940. Innervation of annulus fibrosus and posterior longitudinal ligament. Arch Neurol Psychiatry 44:100–103.

Stillwell DI, Jr. 1956. The nerve supply of the vertebral column and its associated structures in the monkey. Anat Rec 125:139–169.

Wiedersheim R. 1907. Comparative anatomy of vertebrates. 3rd ed. London: MacMillan.

Wilson PO, Barber PC, Hamid QA, Power BF, Dhillon AP, Rode J, Day IN, Thompson RJ, Polak JM. 1988. The immunolocalization of protein gene product 9.5 using rabbit polyclonal and mouse monoclonal antibodies. Br J Exp Pathol. 69:91–104.

Wiltse LL, Fonseca AS, Amster J, Dimartino P, Ravessoud FA. 1993. Relationship of the dura, Hofmann's ligaments, Batson's plexus, and a fibrovascular membrane lying on the posterior surface of the vertebral bodies and attaching to the deep layer of the posterior longitudinal ligament. An anatomical, radiologic, and clinical study. Spine 15:1030–1043.